OP-010

Arthroscopically Assisted Intra-Articular Corrective Osteotomy For Tibial Plateau Malunion

Shih-Sheng Chang
Yi-Sheng Chan
Chang Gung Memorial Hospital
Taiwan

Introduction

Tibial plateau fractures comprise only 1% of all fractures
- It is still challenge to orthopaedic doctors

- Treatment objects for primary Tibial plateau fractures
  - Restored joint congruity
  - Stable Fixation
  - Early ROM
  - Repairing all concomitant lesions

Surgery for Tibial plateau fracture

- Conventional Open Reduction and Internal Fixation
  - Knee arthrotomy
  - Extensive soft tissue dissection
  - High complication rate (50%)
- Arthroscopic reduction and Internal Fixation (ARIF)
  - Minimal soft tissue dissection
  - Precise joint surface reduction
  - Concomitant lesion repair
    - Meniscus lesion
    - ACL/PCL avulsion fracture

Arthroscopic Reduction and Internal Fixation

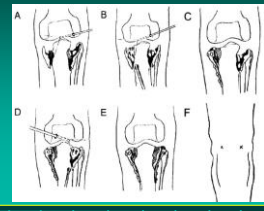

Malunion after Tibial plateau fracture

- Malunion may caused by
  - Severe comminution fracture
  - unstable fixation
  - Inadequate Bone graft
  - Implant failure
  - Infection

Management of Tibial plateau malunion

- To achieve good result, surgeon should
  - Preserved native Knee joint
    - Restore anatomical alignment
    - Restore Stability
    - Restore adequate joint surface congruence
  - Avoid total knee arthroplasty
    - Young patient
    - Long term complications
- Corrective osteotomy is the choice of treatment
  - Difficulties
    - Osteotomy site determination
    - Reduction accuracy
    - Extensive soft tissue dissection

Hypothesis

- Arthroscopic Assisted Corrective Osteotomy (AACO) can treat Titibal plateau fracture malunion
  - Easier determined osteotomy site
  - Better reduction accuracy
  - Less soft tissue dissection
  - Avoid radiation exposure (C-Arm)

Definition of Malunion

- angular deformity exceeding 5 degrees (compared to intact Knee)
- articular surface step-off more than 3 mm
- tibial condylar widening greater than 5 mm.

Fracture classification in 24 cases

Schazker type	I	II	III	IV	V	VI
Patient No	0	5	1	4	7	7

Surgical technique

- All patient put in supine position without leg holder
- A pneumatic tourniquet was applied
- Arthroscopic fluid inflow was achieved with gravity
  - Prevent swelling and compartment syndrome
- Standard arthroscopic portals were created. The tibial incision was made along the previous wound

Evaluation

- Clinical and radiologic outcomes were scored by the modified Rasmussen Scoring system
- Knee alignment was measured from standing scanogram
- The degree of articular depression was measured from the opposite remaining articular surface

Case Presentation

- 53 y/o male after TA

Received ORIF Initially

4 months later in our Clinic

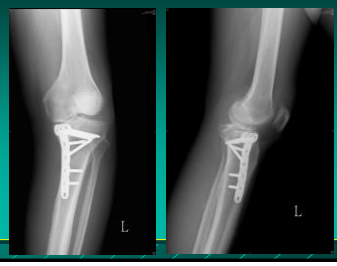

Standing Scanogram

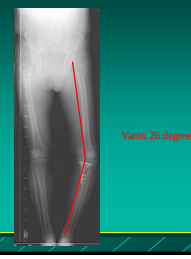

Pre-OP 3D CT

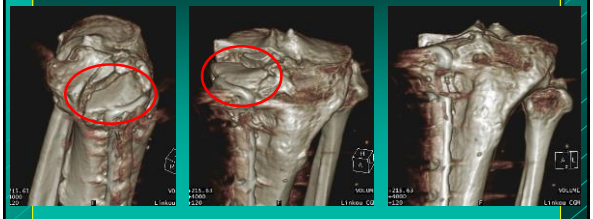

Arthroscopic Assisted Corrective Osteotomy

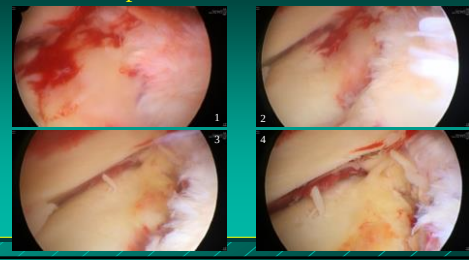

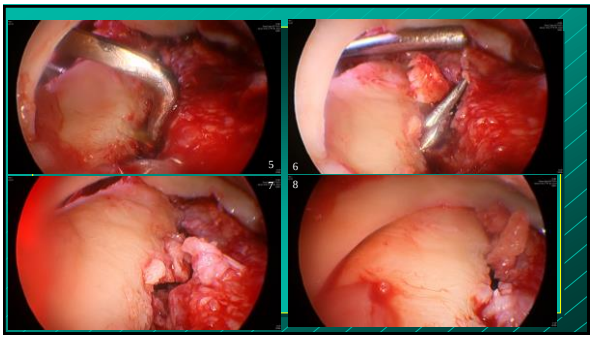

6 months later

RESULTS

Clinical Assessment

- Rasmussen clinical score
  - Before AACO 20.7 (range: 15 to 24)
  - After AACO 27.3 (range 24 to 29) (p = 0)
- Satisfactory rate

	Poor	Fair	Good	Excellent
Before AACO	7	17	0	0
After AACO	0	1	12	11

- Knee ROM
  - Before AACO 98 degrees (range: 30–135 degrees)
  - After AACO 133 degrees (range: 120–135 degrees) (p=0)

Radiologic Assessment

- Joint line depression
  - Before AACO 13.2 mm (4 to 30 mm)
  - After AACO 1.4 mm (0 to 4 mm) (p=0)
- Rasmussen radiologic score
  - Before AACO 5 (range: 4-7)
  - After AAACO 7.8 (range: 6-9) (p=0)
- Knee joint alignment (> 5 degrees varus/ valgus change compared to uninjured knees)

	Genu Varus		Genu Valgus	
Before AACO	15	13.8 degree (4-43)	9	4.2 degree(1-13)
After AACO	3	7 degree (6-9)	0	

Associated injuries

- 11 patients (46%) had associated intra-articular injuries
  - 1 ACL tear
  - 5 PCL tear
  - 3 ACL avulsion fracture
  - 8 meniscus injuries (1 medial and 7 lateral meniscus)
  - One patient had a common peroneal nerve injury before AACO

Complications

- No major complication
  - No neurovascular injury due to AACO
  - No osteomyelitis
  - No DVT
- No patients shift to total knee arthroplasty at final f/u
- One patient had wound stitch abscess and treated with oral antibiotics

DISCUSSION

Tibial plateau fracture malunion

- To perform the corrective osteotomy, knowing the deformed bony structure is essential.
  - 3D CT was highly recommended, However…..
    - Difficult to apply the 3d image in to real time operation
    - Some metal artifacts may influence image quality

Benefit of Arthroscopic Assisted Corrective Osteotomy

- Directly visualize the intra-articular malunion and determine the appropriate osteotomy site
  - osteotomy can be performed easily and precisely without arthrotomy,
  - the malunited fragments can be reduced more accurately
- To treat intra-articular soft tissue lesions simultaneously
  - 46% patient had intra-articular lesion
  - Maybe neglect in conventional osteotomy
- Decrease unnecessary radiation exposure
  - Limited intra-operatively C-arm system

Knee arthroplasty for tibial plateau fracture malunion

- Saleh KJ, JBJS A, 2001
  - 15 cases received TKR after failure of ORIF for tibial plateau fracture
    - Function score ad Pain improved
      - Technique demand
      - High failure rate 33% and **Infection rate 20%**
- Weiss NG, JBJS A, 2003
  - 62 patients received TKR after tibial plateau fracture
    - Poor Soft tissue condition lead to multiple surgeries
    - **Re-operation rate 21%**
    - Infection rate 6.4%

3D print PSI for osteotomy

- Patient Specific Instrument
  - Designed based on 3D CT
  - Improved accuracy of osteotomy

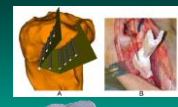

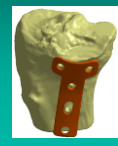

Conclusion

- AACO provides precise reduction, correct alignment, minimal soft tissue stripping, few complications, and adequate treatment in a single-stage surgery.
- The use of this procedure will allow orthopaedic surgeons to maintain the native knee joint and help young patients to avoid the long-term complications associated with total knee arthroplasty.
- 3D print PSI maybe the next step for corrective osteotomy
  - Concomitant arthroscopic examination is still suggested to check soft tissue injuries

Thanks for attention!